



**PATIENT**

Nicki Dohm

**SPECIES**

Canine

**BREED**

Australian Red Heeler

**SEX**

Female Spayed

**AGE**

12.7 years

**WEIGHT**

47.1lbs

**INTERPRETED BY**

Maggie Machen Lamy,  
DVM, DACVIM  
(Cardiology)

**IMAGING PERFORMED BY**

B. Barnes, DVM

**HOSPITAL NAME**

Westview Veterinary  
Hospital

**REFERRING VET**

Dr. Barnes

**INVOICE**

31894

**DATE**

7/17/23

**PRESENTING CLINICAL SIGNS**

History: History of two collapsing events in the last year which were highly suggestive of syncope. The dog has a history of tachyarrhythmias and now has a cardiac murmur, History of hepatopathy. BP: 183mmHg.

**ECHOCARDIOGRAM FINDINGS**

2D, m-mode, color flow and doppler imaging is available. Mild diffuse thickening of mitral valve leaflets with no prolapse into the left atrial lumen. Mild eccentric mitral regurgitation with minimal left atrial dilation. Normal MR velocity. Normal LV diameter with adequate myocardial function. The tricuspid valve appears normal with mild tricuspid regurgitation. Normal velocity. Normal right atrial and ventricular diameter and morphology indicating no overt evidence of pulmonary arterial hypertension. The pulmonic and aortic valves are normal in morphology and mobility. Normal pulmonic and aortic outflow velocities with laminar flow. No obvious aortic and trace pulmonic insufficiency. No pericardial or pleural effusion noted. No obvious cardiac masses.

**CARDIAC CHART**

CANINE CARDIAC PARAMETERS	MR VMAX (m/s)	TR VMAX (m/s)	LA/AO (Boon method)	LA/AO (Heart Base; Swe)	FS (%)	EF (%)	EPSS (cm)
NORMAL PARAMETER	4.5-5.5	<2.7	1.3	<1.6	28-40	40-100	<0.6
PATIENT	5.1	2.0	1.4	1.4	29	57	0.3
CANINE CARDIAC PARAMETERS	HR (BPM)	AV VMAX (m/s)	PV MAX (m/s)	BODY WEIGHT (kg)	LA 2D short axis Base view (cm)	LVIDd Avg; 2D and m-mode short axis (cm)	LVIDs Avg; 2D and m-mode short axis (cm)
NORMAL PARAMETER	50-100	0.7-1.7	0.7-1.6	BELOW	BELOW	BELOW	BELOW
PATIENT	NM	0.95	0.55	21.4	2.5	3.4	2.4
*Normal chamber parameters expressed as a mean value (SD)							
<b>BODY WEIGHT DEPENDENT PARAMETERS</b>							
<i>*Note: All measurements based upon multi-modal images and methods. An average value is reported.</i>							
Adapted from June Boon, Veterinary Echocardiography, 1998							
Rishniw M and Hollis NE, J Vet Intern Med 2000; 14:429-435							
Hansson et al, Vet Rad and Ultrasound 2002							
Bonagura et al. Echocardiography: principles of interpretation, Vet Clin North Am 15:1177, 1995							
3 1.27 (5.3) 2.46 (2.46) 1.36 (5.5)							
5 1.40 (4.5) 2.74 (5.2) 1.60 (4.7)							
10 1.50 (3.8) 3.27 (3.5) 2.06 (3.1)							
15 1.83 (2.0) 3.71 (2.4) 2.43 (2.1)							
20 2.02 (1.9) 4.14 (2.2) 2.80 (2.0)							
25 2.18 (2.4) 4.48 (2.9) 3.10 (2.5)							
30 2.33 (3.3) 4.83 (3.9) 3.39 (3.4)							
35 2.48 (4.3) 5.17 (5.0) 3.69 (4.5)							
40 2.62 (5.2) 5.48 (6.1) 3.96 (5.4)							
50 2.88 (7.1) 6.07 (8.3) 4.46 (7.4)							

**INTERPRETATION OF THE FINDINGS & FURTHER RECOMMENDATIONS**

Chronic degenerative valve disease causing mild mitral and trace tricuspid regurgitation. Lack of significant left atrial enlargement indicates the current risk for complication is low. No concurrent issues such as systolic dysfunction or pulmonary hypertension are noted in this study.

No structural cause for syncope is identified in this study and other possibilities should be considered. **In a patient with a history of arrhythmic disease, a screening ECG is certainly reasonable.** A holter monitor may be warranted in this case if no cause is identified.



**PATIENT**

Nicki Dohm

**SPECIES**

Canine

**BREED**

Australian Red Heeler

**SEX**

Female Spayed

**AGE**

12.7 years

**WEIGHT**

47.1lbs

**INTERPRETED BY**

Maggie Machen Lamy,  
DVM, DACVIM  
(Cardiology)

**IMAGING PERFORMED BY**

B. Barnes, DVM

**HOSPITAL NAME**

Westview Veterinary  
Hospital

**REFERRING VET**

Dr. Barnes

**INVOICE**

31894

**DATE**

7/17/23

In a dog with no significant left atrial enlargement, no cardiac medications are clearly indicated. Assessment of progression in the future will help predict long term prognosis, which is highly variable at this stage (B1). Omega fatty acid supplementation and mild salt restriction may be of some long-term benefit. Monitor for development of a cough, labored breathing, exercise intolerance or collapse episodes.

The reported blood pressure is elevated and should be reassessed for accuracy particularly given no reported clinical signs of severe hypertension (retinal changes, etc.) or evidence of LVH on echo. Ideally obtain serial measurements in a controlled, low stress environment and continue until 3 consecutive readings plateau within 5mmHg of variability. If persistently >180mmHg despite a relatively calm demeanor, recommend institution of amlodipine to effect. Additionally, if deemed accurate, screening for predisposing underlying causes of SHT is recommended (Cushing's, PLN, adrenal tumor, etc.), as primary disease is relatively uncommon and a rule out diagnosis.

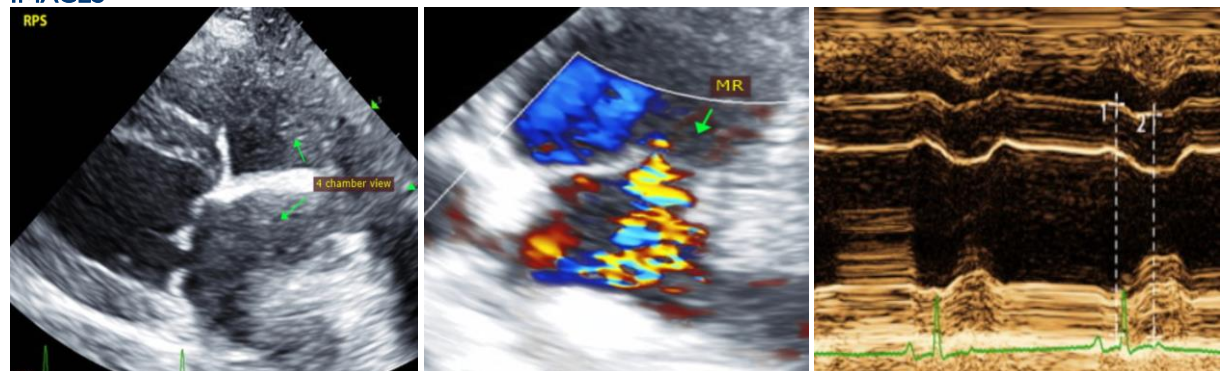
Anesthetic risk is considered mild if needed. Cardiac protective drug choices (opioid/benzodiazepine premedication, propofol or alfaxalone induction, isoflurane gas) are recommended. Pre-oxygenate for 5-10 minutes prior to induction. Monitor for arrhythmias, hypotension, and hypoxia both intra and post-operatively and intervene as necessary. Mild IV fluid restriction is recommended to avoid fluid overload. Avoid heart rate stimulating drugs such as atropine unless clinically indicated.

**PLAN**

Consider further evaluation of reported syncope, included an ECG/holter monitor, reassess BP, etc.

Recommend conservative monitoring with a recheck echocardiogram in 6-12 months, sooner if any development of clinical signs.

**IMAGES**



The information and recommendations provided are based on the images presented by the referring veterinarian. No evaluation can be communicated regarding pathology that was not visible in the image/video clips provided.

Thank you for this referral. This report was generated using transcription software, and minor dictation errors may be present. If the clinical or image interpretation does not parallel your findings or if I can be of any further assistance, please contact me.

**Maggie Machen Lamy, DVM**  
Diplomate of the American College of Veterinary Internal Medicine (Cardiology)  
info@sonopath.com